

Femoral shaft bowing with age: a digital radiological study of Anatolian Caucasian adults

Hakki Muammer Karakaş, Ahmet Harma

PURPOSE

To determine the dimensions of the femoral shaft and their relationship to age in Anatolian Caucasian men and women.

MATERIALS AND METHODS

Maximum femoral length (MFL), mid-shaft transverse diameter (MTD), and anterior bowing (AB) were studied in a sample of 104 adults. The linear dimensions and AB of the femoral shafts were measured on digital images.

RESULTS

In males, mean MFL, MTD, and AB were 448.2 mm, 26.5 mm, and 759.3 mm, respectively. In females these measurements were 419.0 mm, 25.6 mm, and 779.5 mm. Males had longer MFL ($P < 0.0001$) and there was no difference between males and females regarding the other parameters. MFL and age were correlated in females ($r = -0.374$, $P < 0.005$), whereas they were not correlated in males. In females, MFL decreased until about 45 years of age and stabilized thereafter. MTD was correlated with age in males ($r = 0.428$, $P < 0.002$), increasing from adolescence to maturity. This correlation was insignificant in females and there was only a slight increase in diameter after about 30 years of age. AB and age were significantly correlated in females ($r = -0.401$, $P < 0.003$), with AB continuously increasing with age. The correlation between AB and age was insignificant in males.

CONCLUSION

The increase in bone cross-sectional area in aging males may contribute to the maintenance of adequate mechanical competence throughout adulthood. In females this compensatory mechanism appears to be much less efficient and, accordingly, the end result of this process is AB of the femur and inevitable shortening of the bone.

Key words: • bone • aging • femur morphometry

Bone mass changes with age have been well described and are characterized by an increase during childhood and adolescence, maintenance during middle age, and a decline after about 50 years of age (1–3). These changes differ in men and women (3, 4). The difference is determined by sex hormones during puberty and results in female bones being inherently smaller than those of men (5). However, descriptions of morphometric changes, both in terms of shape and dimension, are limited.

Concerning the femur, morphometric studies on aging have mainly focused on the proximal part of the bone. The morphometry of the shaft has not been investigated to the same extent, as it is stronger than the proximal part and is not prone to age-dependent fractures. All the studies we were able to locate were either conducted to determine the compatibility of the femoral medulla with intramedullary nails (6, 7) or to explore ethnic, racial, and gender differences (8–13).

Weight-bearing bones are continuously subjected to external forces (mechanical loading), which cause the form and structure of bones to change (14, 15). The femoral shaft is known to experience mechanical loading in the form of compression or bending stress, which causes a special reaction known as plastic deformation (16). Characteristics of this reaction are permanent bowing of a long tubular bone without fracture and the lack of periosteal reactions in follow-up X-rays. Periosteal expansion, which causes morphological changes with age, may develop to offset such mechanical effects.

In the present study, natural variations in femoral shaft geometry, in relation to age and gender, were investigated to identify possible differential mechanisms of bone aging in males and females.

Materials and methods

Study subjects

The study subjects were Caucasian adults living in eastern Anatolia. They presented to our institution for irrelevant minor causes, such as otorhinolaryngological or dermatological problems, or they were recruited from among the companions of patients that presented to the same institution. The institutional review board for clinical investigation at this facility approved the study protocol and informed consent was obtained from all subjects.

Subjects were excluded if they had any chronic illness or if they were physically inactive. All subjects underwent a general physical examination performed by an orthopedist and were excluded from the study if any orthopedic disorder was found. The final group consisted of 104 subjects (50 male and 54 female) aged between 18 and 68 years (mean age, 40.9 years; SD, 14.7 years). These same subjects also participated in other clinical studies on femoral nails (6) and forensic medicine (13).

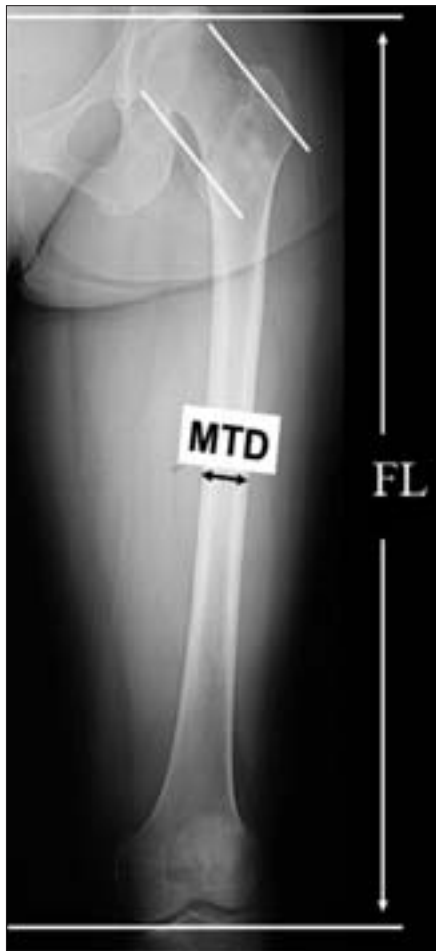

Figure 1. Scanogram of the left femur in the anteroposterior projection. Maximum femoral length (FL) and mid-shaft transverse diameter (MTD) measurements are seen.

Femoral measurements

Anteroposterior and lateral digital radiographic views (computed tomography [CT] scanograms) of both legs were obtained using a CT scanner (Tomoscan Secura, Philips, Best, The Netherlands). We preferred this method because in scanogram mode current spiral CT scanners have the capability of obtaining a continuous digital image up to 180 cm or more. The field of view obtained with this method is much larger than that obtained with the flat panel detectors currently used with digital radiography equipment, which provide a field of view less than 40 cm. A large field of view is necessary to image long structures such as the femur or the entire body. CT also has the advantage of performing sectional imaging during the same session and of archiving the raw images in DICOM (Digital Imaging and Communications in Medicine) format for future studies.

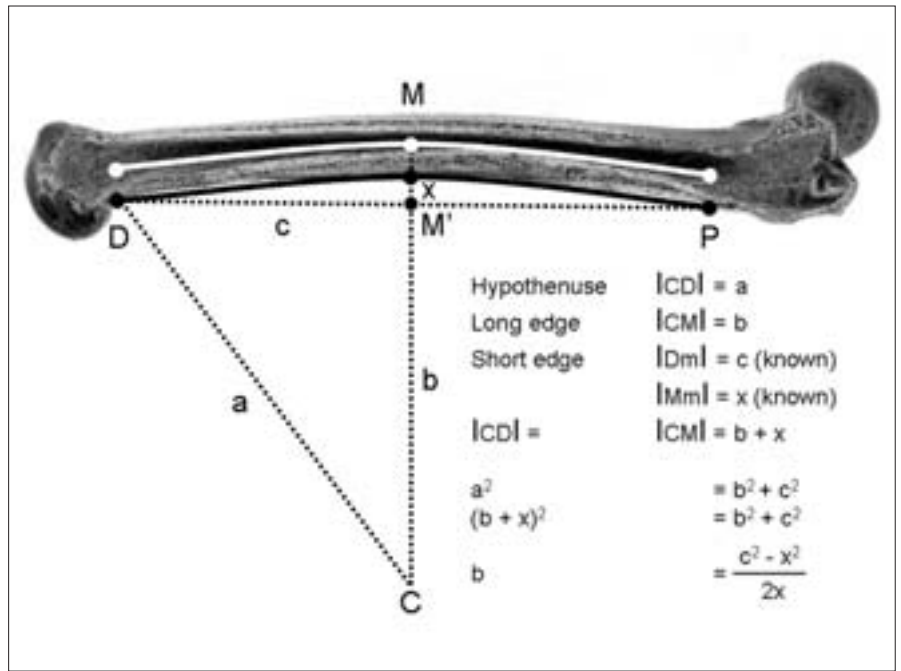


Figure 2. The computation of anterior bowing on the representative digital image in the lateral projection.

Anteroposterior and lateral scanograms were obtained with subjects in the supine position. For anteroposterior views, both legs were extended. For lateral views, a sponge pillow was placed beneath the right hip in order to keep it flexed between 40 and 45 degrees. This method prevents proximal radiological overlapping of the right and left femurs. For lateral views, the detector array was situated on the left side of the scanner. The magnification of the longitudinal dimensions was minimal with the scanogram, but certainly present in the transverse direction. Therefore, the left femur, which was closer to the scanner's detector array and relatively free of magnifying effects, was used for the measurements. Radiographic views were hard copied onto video film on which measurements were performed.

Maximum femoral length (MFL) and mid-shaft transverse diameter (MTD) were measured on frontal views, according to the method of Martin and Saller (12) (Fig. 1). MFL was the maximum distance from the uppermost margin of the head of the femur to the lowest margin of the medial condyle. MTD was the transverse diameter at the middle of the shaft.

Anterior bowing (AB) was measured on lateral views, according to the method of Harma and Karakaş (6, 13). With

this method femoral curvature was accepted as an arch and the radius of the imaginary circle to which this arch might belong was calculated, starting from the posterior cortex. The 3 points that formed the posterior cortical arch were defined as follows: 1. proximal, the lower edge of the lesser trochanter (P); 2. distal, where the widening of the condyle begins (D); 3. midpoint, the half distance between the proximal and distal points (M). After the determination of these reference points, the line connecting P and D (PD) was traced. The distance between P and D, and the shortest distance between line PD and point M (Mm) was measured. The radius of the imaginary circle that this PMD arch belonged to (namely the length of the hypotenuse of the triangle CmD) was calculated using the formula $a^2 = b^2 + c^2$ (Fig. 2).

Statistical analysis

All results are expressed as the mean \pm SD. Data were analyzed using Student's t-test for independent samples, and Pearson's moment correlation coefficients. $P < 0.05$ was accepted as the level of significance.

Results

In males, mean MFL was 448.2 mm, mean MTD was 26.5, and mean AB was 759.3 mm. In females these measure-

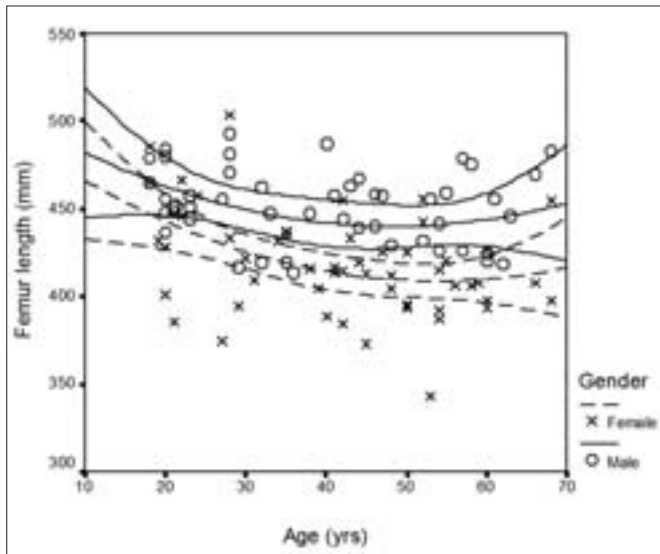


Figure 3. Scatter plot showing the relationship between age and maximum femoral length.

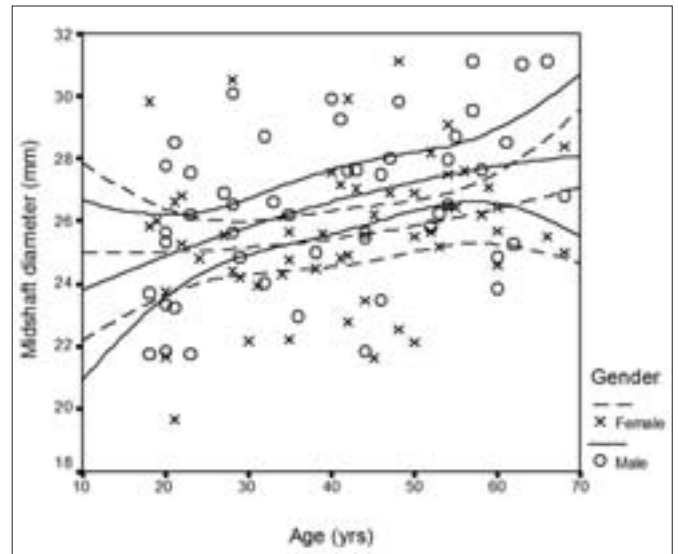


Figure 4. Scatter plot showing the relationship between age and femoral mid-shaft transverse diameter.

ments were 419.0 mm, 25.6 mm, and 779.5 mm, respectively (Table). There was a significant difference between males and females regarding MFL ($P < 0.0001$), and males had greater MFL than females. There was no statistical difference between males and females regarding MTD and AB.

MFL and age were significantly correlated in females ($r = -0.374$, $P < 0.005$), whereas no significant correlation was present in males. Apparent MFL decreased until 45 years of age in females and remained constant thereafter (Fig. 3). MTD was significantly correlated with age in males ($r = 0.428$, $P < 0.002$), whereas this correlation was insignificant in females. The related scatter plot exhibited an increase in MTD from adolescence to maturity in males. In females there was only a slight increase in diameter after 30 years of age (Fig.

4). AB and age were significantly correlated in females ($r = -0.401$, $P < 0.003$), in whom AB continuously increased (i.e. a decrease in AB value that shows the radius) until 55 years of age (Fig. 5). AB and age were insignificantly correlated in males.

Discussion

In this study male femurs were longer than those of females. As stated in the introduction, this difference is determined by sex hormones during puberty and results in female bones being inherently smaller than those of men (5). In females apparent MFL was significantly correlated with age, decreasing until 45 years of age and remaining constant thereafter (Fig. 3).

The femur is subjected to continuous external forces that alter its form and structure. We postulate that age-

dependent shortening of the femur is at least partly due to axial loading and bending forces. These changes are known to depend on the remodeling process, which is oriented to these mechanical forces and serves as a protective mechanism. In this context, vertebral bodies, for example, are subjected mainly to compressive forces, and show an age-independent constant height and an age-dependent increase in maximum width (15, 17). Results of the present study suggest the existence of a similar mechanism for femurs in males. MTD of the femoral shaft exhibited a significant increase in males from adolescence to maturity, possibly helping to conserve MFL. In contrast, females did not exhibit an increase in MTD (Fig. 4). Stability of MTD accompanied a decrease in MFL. A similar phenomenon was observed in tibial bones

Femoral shaft parameters according to gender

	Parameter	n	Minimum	Maximum	Mean	SD
Male	MFL	50	293.3 mm	492.7 mm	448.2 mm	30.5 mm
	MTD		21.8 mm	31.1 mm	26.5 mm	2.5 mm
	AB		117.8 mm	1665.7 mm	759.3 mm	269.6 mm
Female	MFL	54	342.7 mm	503.3 mm	419.0 mm	29.1 mm
	MTD		19.7 mm	31.1 mm	25.6 mm	2.3 mm
	AB		108.8 mm	1665.7 mm	779.5 mm	267.4 mm

MFL: maximum femoral length; MTD: mid-shaft transverse diameter; AB: anterior bowing; SD: standard deviation.

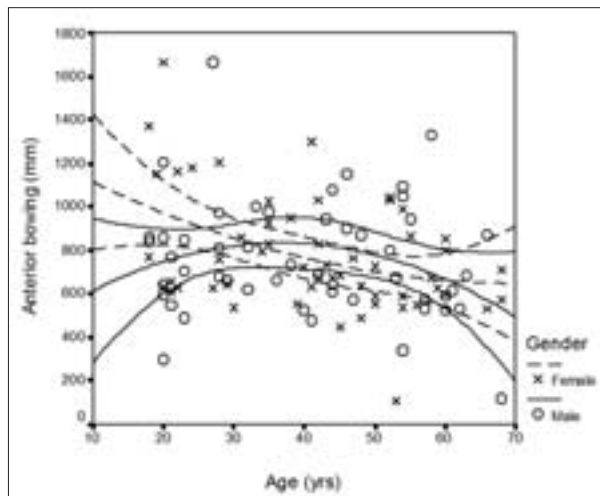


Figure 5. Scatter plot showing the relationship between age and anterior bowing of the femoral shaft.

by Russo et al. (3). Using quantitative CT they assessed trabecular and cortical bone density and mass, and geometric distribution at the tibial level in males and females aged between 20 and 102 years. According to their findings, trabecular and cortical bone density decreases linearly with age and the slope of age-associated decline is steeper in women than in men. The total cross-sectional area of the bone become progressively wider with age, but the magnitude of the age-associated increment was significantly greater in men than in women. The minimum moment of inertia, an index of mechanical resistance to bending, remained stable with age in men, while it was significantly lower in older women than in younger women (0.5% per year) (3).

In females, femoral shortening was thought to originate from AB. This assumption was supported by the presence of a significant correlation between this parameter and age in females. In females there was a constant increase in AB until about 55 years of age (Fig. 5). This parameter is known to show no racial or gender difference, at least by itself (3, 8). According to Gilbert (8), femora of African American and American Caucasian individuals with low ponderal indices are less bowed than the norms for their race; femora of individuals with high ponderal indices are more bowed than the norm for their race. Gilbert further assumed that the genetic basis for the expression of anterior femoral curvature suggested by earlier studies seemed to be a feature of human plastic response

to body weight rather than to temporal, postural, or equestrian influences (8). In addition to Gilbert's assumption, we think that the degree of bowing is also determined by counteractive mechanisms, such as enlargement of the femoral shaft; however, we did not record the body dimensions and weights of our subjects, as the original study from which these measurements were obtained did not necessitate such measurement (6). Nevertheless, this constitutes a major limitation of the present study. In future studies on this subject, the dimensions should be corrected for these measures. Certainly men in our sample had larger bodies than did the women and this is apparent in the differences in MFL. In much of Europe, and certainly Turkey, older subjects endured much privation during their youth and thus have smaller bodies. It is also possible that the greater degree of femoral AB in older women may have had origins in greater levels of physical work and carrying heavy load during their youth.

In conclusion, the increase in femoral MTD in growing males may contribute to the maintenance of adequate bone mechanical competence during adulthood. In females, this compensatory mechanism appears to be much less efficient and, accordingly, female bone mechanical competence declines with age. The end result of this process is the apparent AB of the femur and inevitable apparent shortening of the bone. Further densitometric and trabecular studies on the femoral shaft may delineate the exact influence of

mechanical loading and differential processes, which may counteract those axial forces. In this respect, the effectiveness of different anti-resorptive agents on femoral bowing, alone or in combination with exercise, has yet to be determined.

References

1. Ballabriga A. Morphological and physiological changes during growth: an update. *Eur J Clin Nutr* 2000; 54 Suppl 1:S1-6.
2. Mosekilde L. Mechanisms of age related bone loss. *Novartis Found Symp* 2001; 235:150-166.
3. Russo CR, Lauretani F, Bandinelli S, et al. Aging bone in men and women: beyond changes in bone mineral density. *Osteoporos Int* 2003; 14:531-538.
4. Mosekilde L. Bone structure and function in relation to aging and the menopause. *Maturitas* 1997; 27 Suppl 1:4.
5. Rizzoli R. Determinants of peak bone mass. *Ann Endocrinol (Paris)* 2006; 67:114-115.
6. Harma A, Germen B, Karakas HM, Elmali N, Inan M. The comparison of femoral curves and curves of contemporary intramedullary nails. *Surg Radiol Anat* 2005; 27:502-506.
7. Harper MC, Carson WL. Curvature of the femur and the proximal entry point for an intramedullary rod. *Clin Orthop* 1987; 220:155-161.
8. Gilbert BM. Anterior femoral curvature: its probable basis and utility as a criterion of racial assessment. *Am J Phys Anthropol* 1975; 45:601-604.
9. Gill WG. Racial variation in the proximal and distal femur: heritability and forensic utility. *J Forensic Sci* 2001; 46:791-799.
10. Hrdlicka A. The human femur: shape of the shaft. *Am J Phys Anthropol (Anthropologie, Praha)* 1934; 12:129-163.
11. Stewart TD. Anterior femoral curvature: it's utility for race identification. *Hum Biol* 1962; 34:49-62.
12. Trudell MB. Anterior femoral curvature revisited: race assessment from the femur. *J Forensic Sci* 1999; 44:700-707.
13. Harma A, Karakas HM. Determination of sex from femur in Anatolian Caucasians: a digital radiological study. *J Forensic Leg Med* 2007; 14:190-194.
14. Henschke F, Pesch HJ. The structure of the spongy bone in lumbar vertebrae and the neck of the femur: a comparative analysis of the age-dependent remodelling process. *Microsc Acta Suppl* 1980; Suppl 4:124-128.
15. Cvijanovic O, Bobinac D, Zoricic S, et al. Age- and region-dependent changes in human lumbar vertebral bone: a histomorphometric study. *Spine* 2004; 29:2370-2375.
16. Povacz F. Plastic deformity of the long tubular bones. *Unfallchirurgie* 1988; 14:38-42.
17. Scharf HP, Pesch HJ, Lauer G, Seibold H. Changes in form and structure of vertebrae as a manifestation of mechanical loading. *Microsc Acta Suppl* 1980; Suppl 4:129-134.